

## **Full Mouth Rehabilitation In Genetic Disorder Patients- A Retrospective Study**

**Nashwah Hinaz**

Saveetha Dental College And Hospitals  
Saveetha Institute Of Medical And Technical Sciences  
Saveetha University  
Chennai, India  
Mail Id: 151601041.Sdc@Saveetha.Com

**Ashok V**

Professor, Department Of Prosthodontics  
Saveetha Dental College And Hospitals  
Saveetha Institute Of Medical And Technical Sciences,  
Saveetha University  
Chennai, India  
Mail Id: Ashok@Saveetha.Com

### **Abstract**

**Aim:** The Aim Of The Study Is To Evaluate Full Mouth Rehabilitation Done In Genetic Disorder Patients.

**Materials And Methods:** Data Was Collected After Reviewing The Patient Records And Analyzed Between June 2019 To March 2020. The Collected Data Is Tabulated And Software Analysis Spss To Obtain Results.

**Results:** Total Of 233 Cases Reported For Full Mouth Rehabilitation. 17.6% Of The Age Group 20 To 39 Years, 51% Of The Age Group 40 To 59 Years And 31.3% Of The Age Group 80 To 90 Years. A Total Of 52.59% Cases Were Treated With Fmr And 4.31% Of Patients With Genetic Disorders.

**Conclusion:** Within Limitations Of This Study, Most Genetic Disorder Patients With Dental Anomaly Have Undergone Full Mouth Rehabilitation. Education And Awareness Should Be Given To The Genetic Disorder Patients Who Have Such Dental Anomalies To Improve Their Self Confidence In The Society.

**Key Words:** Full Mouth Rehabilitation; Genetic Disorder; Reconstruction; Oral Cavity

### **Introduction**

Dental Esthetics Is Of Prime Importance For Young Adults As It Positively Influences Their Self-Confidence, Social Life, And Overall Well-Being[(1)]. New Advances In The Field Of Dentistry Have Contributed To Better Smiles Worldwide[(2)]. Severely Debilitated Oral Conditions Which Involve The Majority Of Teeth, Demand For More Comprehensive And Multidisciplinary Treatment [(3,4)]. The Objective Of Full Mouth Rehabilitation (Fmr)Is Not Only The Reconstruction And Restoration Of The Worn Out Dentition, But Also Maintain The Health Of The Entire Stomatognathic System [(5,6)]. Full Mouth Rehabilitation Should Re-Establish A State Of Functional As Well As Biological Efficiency Where Teeth And Their Periodontal Structures, The Muscles Of Mastication, And The Temporomandibular Joint (Tmj) Mechanisms All Function Together In Synchronous Harmony [(7)]. Proper Evaluation Followed By Definitive Diagnosis Is Mandatory As The Aetiology Of Severe Occlusal Tooth Wear Is Multifactorial And Variable [(8).] Careful Assessment Of The Patient's Diet, Eating Habits And/Or Gastric Disorders, Genetic Disorders, Is Essential For Appropriate Treatment Planning [(9,10)] . The Restoration Of Normal Healthy Function Of The Masticating Apparatus Is The Ultimate Aim Of Full Mouth Rehabilitation [(11)]. Genetic Disorders Are Far More Common Than Is Widely Appreciated And The Genetic Diseases Encountered In Medical Practice Represent Only The Tip Of The Iceberg [(12)]. Progress In Genetics And Molecular Biology Has Resulted In The Emergence Of New Concepts To Explain The Etiology And Pathogenesis Of Many Human Disease Processes Including Oro-Dental Diseases [(13)]. More Than 300 Genes Are Involved In Determination Of The Position,

Number, And Shape Of Different Types Of Teeth [(14)]. Mutations In Those Genes Encoding Transcription Factors And Signaling Molecules Involved In Odontogenesis Is Responsible For Numerous Abnormalities Of The Teeth [(15)]. Tooth Agenesis Is The Most Common Craniofacial Malformation. In Syndromic Tooth Agenesis, It Is Associated With Various Syndromes Because Many Genes Take Part In Molecular Mechanisms Common To Tooth And Other Organs Development [(16)]. The Following Are The Commonly Associated Syndromes Are Ectodermal Dysplasia, Cleidocranial Dysplasia. Structural Tooth Defects- Amelogenesis Imperfecta, Dentinogenesis Imperfecta, Dentin Dysplasia. Syndrome Related -Autism, Down's Syndrome [(17)].

Various Studies Have Been Done Based On The Need Of Full Mouth Rehabilitation In Patients With Genetic Disorders, However These Studies Face Certain Challenges . In A Study By Bencharit S Et Al, Full Mouth Rehabilitation Is Done For A 33 Year Old Female Patient With Dentinogenesis Imperfecta Type Ii ,Which Is A Genetic Disorder Affecting The Development Of The Dentin. The Challenges Faced Was That The Treatment Was Complex And Difficult Depending On The Loss Of Tooth Structure And Missing Teeth, Severity Of Enamel Fracturing, Attrition, And Pulpal Involvement. Pulpal Obliteration Or Large Pulp Chambers Present Challenges To Endodontic Therapy And Restoration [(18)]. Similarly In A Study By Khandelwal S, Et Al, On A Patient With Dentin Dysplasia, An Autosomal Dominant Hereditary Disturbance In Dentin Formation, And In A Study By Sreedevi S,Et Al About Amelogenesis Imperfecta, It Is Observed That The Challenges Faced Were Difficulty In Management And Provision Of A Restorative, Endodontic Treatment And Prosthetic Treatment After Loss Of Teeth [(19,20)]. The Most Common Challenge Faced Is Also Patient Cooperation, As Most Patients Are Young When Diagnosed With A Genetic Disorder Which Also Leads To Severe Stress And Strain During Treatment [(21,22)].

This Study Is Required To Evaluate The Correlation Of Genetic Disorders With Defects In Teeth And It's Structure And The Importance To Restore It With Comprehensive Treatment With Proper Diagnosis And Treatment Planning. Previously Our Team Has A Rich Experience In Working On Various Research Projects Across Multiple Disciplines The (23–25)(26–37). The Aim Of The Study Is To Evaluate Full Mouth Rehabilitation Done In Genetic Disorder Patients.

## Materials And Methods

A University Based Study Was Conducted Among 233 Patients, In The Age Group 20-80 Years From June 2019 To March 2020 Out Of Which Nine Genetic Disorder Cases Were Observed. These Included Patients Reporting With Autism, Cleidocranial Dysplasia, Congenital Hydrocephalus Schizencephaly, Downs Syndrome, Ectodermal Dysplasia, Idiopathic/Familial Pulmonary Fibrosis, Parkinson's Syndrome .

Data Was Collected After Analyzing The Patient Record In A Specific Period Of Time. The Study Was Conducted With The Approval Of The Institutional Ethics Committee [Sdc/Sihhec/2020/Diasdata/0619-0320]. Population Selection Was Random And The Population Type Included Outpatients Preferably Adults.

Sampling:

The Data Collected Was Cross Verified With Photographs. Bias Was Avoided By Including All Available Data. The Confounding Factors Were Eliminated And The Results Can Be Applied In Practical Situations. Data Collection And Tabulation Was Done.

Statistical Analysis:

Data Was Exported To Spss Windows Version 20 (Ibm) For Data Checking ,It Was Sorted And Presented Using Graphs, Charts And Tables. The Independent Values Were Age And Sex Of Patient. The Type Of Analysis Was Correlation And Association.

## Results

Table 1 Shows The Types Of Genetic Disorder Cases That Were Reported At Saveetha Dental College Out Of The Total 233 Cases That Were Reported For Fmr. The Genetics Disorder Cases Included Patients Reporting With Autism, Cleidocranial Dysplasia, Congenital Hydrocephalus Schizencephaly, Downs Syndrome, Ectodermal Dysplasia, Idiopathic/Familial Pulmonary Fibrosis, Parkinson's Syndrome .

A Total Of 233 Patients Reported To The Clinic For Full Mouth Rehabilitation Procedures. The Age Range Was From 20-90 Years. 41 Cases(17.6%) Were Reported In The Age Group 20-39 Years , 119 Cases (51.07%) Were Reported In The Age Group 40-59 Years, 73 Cases (31.33%) Were Reported In The Age Group 60-90 Years As Shown In Figure 1.

Out Of 233 Patients Reporting To The Clinic, 123 Cases (52.59%) Were Treated By Full Mouth Rehabilitation And 110 Cases (47.41%) Were Not Treated By Full Mouth Rehabilitation As The Patients Were Not Willing For Treatment As Shown In Figure 2.

Out Of The 233 Patients Who Reported To The Clinic, Only 9 Cases ( 4.31%) Had Patients With Genetic Disorders Requiring Full Mouth Rehabilitation And The Remaining 224 Cases (95.69%) Had Patients Requiring Full Mouth Rehabilitation But Did Not Have A Genetic Disorder, As Shown In Table 3. Figure 4 shows Association Of Total Number Of Genetic Disorder Cases Treated With Fmr And Non Genetic Disorder Cases Treated With Fmr With Total Full Mouth Rehabilitation Cases., 4.31% Cases With Genetic Disorder Have Been Treated With Fmr.

## **Discussions**

In The Current Study, The Prevalence For Full Mouth Rehabilitation Was Highest In The Age Group 40 To 59 Years With 51.07% Followed By 31.33% And 17.6% In The Age Group 60 To 90 Years And 20-39 Years Respectively. However, In A Study By Aljeaidi Et Al, Fmr Was Done For A Patient Aged 28 Years. One Of The Most Important Factors To Consider During A Full Mouth Rehabilitation Is Both Age And Health Of The Patient. Younger Patients Recover Faster From Treatment Than Older Ones [(38)]. In A Study By Bencharit S Et Al, Full Mouth Rehabilitation Was Done For A 33 Year Old Female [(18)]. It Is Also Seen That The Age Group 60-90 Years Require Fmr Mainly Due To Wear Of The Tooth Structures Over Time And Not Due To Genetic Disorders. Similarly In A Study By Song My, A 77-Year-Old Woman Was Referred For Treatment Due To Severely Worn Out Dentition And In A Study By Moslehifard E, A 46-Year-Old Man Was Referred For Restoration Of His Worn And Missing Teeth. The Possible Cause Of Such Conditions Might Be Parafunction, Eating Habit, And Dental Ignorance [(39,40)].

Genetic Disorder Cases That Report To The Clinic Are Comparatively Low Though It Is Highly Prevalent In The Country [(41,42)]. In This Study, Genetic Disorder Contributed 4.3% Out Of The Total 49.35% Cases Treated For Fmr. Two Patients Reported For Full Mouth Rehabilitation With Hypohidrotic Ectodermal Dysplasia And Ed Respectively. Similarly In A Study By Anuroopa A Et Al, A 17-Year-Old Female Patient Presented With Hypohidrotic Ectodermal Dysplasia. Significant Oral Findings Include Hypodontia (80%), Loss Of Occlusal Vertical Dimension And Lack Of Normal Alveolar Ridge Development. Prosthetic Management Of Ectodermal Dysplasia By Enhancing The Appearance And Function Through Full Mouth Rehabilitation With A Long-Span Fixed Partial Denture Designed Using A Custom Made Broadrick Flag [(43)]. Similarly, Koyuncuoglu Cz Et Al, Reported A 22-Year-Old Male Patient With Ectodermal Dysplasia Who Had All Permanent Teeth Missing Except For The Maxillary Central Incisors. The Maxilla Was Rehabilitated With A Tooth-Supported Telescopic Partial Denture While The Mandible Was Restored With An Implant And Teeth-Supported Prosthesis [(44)].

A Patient With Cleidocranial Dysplasia Reported In This Current Study. Similarly, In A Study By Atil F Et Al, A Patient With Cleidocranial Dysplasia Had Reported Which Is An Uncommon, Generalized Skeletal Disorder Characterized By Delayed Ossification In Various Sites And Also Caused Complex Dental Abnormalities. Oral Rehabilitation With Implant-Supported Fixed Dental Prostheses In The Maxilla And Mandible Of The Patient Was Planned [(45)]. Patients With Down's Syndrome And Autism Were Also Reported In This Study. Similarly, Ribeiro Cg Et Al, Reported A 36-Year-Old Woman With Down Syndrome. Oral Findings Included Microgenia, Macroglossia, Microdontia Of Permanent Dentition, Altered Crown Morphology And Shape, Enamel Hypoplasia And Hypocalcification, Taurodontism, And Hypodontia. Full Mouth Rehabilitation Was Planned By Carefully Considering Every Tooth Present In The Oral Cavity [(46)]. Our Institution Is Passionate About High Quality Evidence Based Research And Has Excelled In Various Fields ( 47-57). The Limitations Of The Study Is A Limited Population, A Larger Sample Related To The Genetic Disorder Can Be Assessed Over A Longer Period Of Time [(58,59)]. The Future Scope Of The Study Is That Other Parts Of The Population Should Be Covered With A Larger Population.

## **Conclusion**

Within The Limitations Of This Study, Most Genetic Disorder Patients With Dental Anomaly Have Undergone Full Mouth Rehabilitation. Education And Awareness Should Be Given To Such Patients. Individuals Affected By Genetic Disorders Show The Correlation Of Abnormalities In The Teeth With Various Genetic Conditions. Hence, Full Mouth Rehabilitation Is Of Utmost Importance For Treating Such Patients With Genetic Disorders That Affect The Teeth For Functional And Psychosocial Reasons.

## **Acknowledgement**

The Authors Would Like To Acknowledge The Chancellor, Director Of Academics, The Principal, Associate Dean Of Research And The Vice Chancellor, Saveetha University. We Would Also Like To Acknowledge The Head Of Department, Professors, Guide, Readers, Lecturers, And Their Fellow Graduates, Department Of Prosthodontics, Saveetha University.

#### Author Contributors

All Authors Have Contributed Equally In Writing The Manuscript Of This Study.

#### Conflict Of Interest

There Were No Conflicts Of Interest As Declared By The Authors.

#### References

1. Jain Ar, Nallaswamy D, Ariga P, Ganapathy Dm. Determination Of Correlation Of Width Of Maxillary Anterior Teeth Using Extraoral And Intraoral Factors In Indian Population: A Systematic Review. *World J Dent.* 2018;9:68–75.
2. Jyothi S, Robin Pk, Ganapathy D, Others. Periodontal Health Status Of Three Different Groups Wearing Temporary Partial Denture. *Research Journal Of Pharmacy And Technology.* 2017;10(12):4339–42.
3. Klages U. Dental Aesthetics, Self-Awareness, And Oral Health-Related Quality Of Life In Young Adults [Internet]. Vol. 26, *The European Journal Of Orthodontics.* 2004. P. 507–14. Available From: [Http://Dx.Doi.Org/10.1093/Ejo/26.5.507](http://Dx.Doi.Org/10.1093/Ejo/26.5.507)
4. Klages U, Bruckner A, Guld Y, Zentner A. Dental Esthetics, Orthodontic Treatment, And Oral-Health Attitudes In Young Adults [Internet]. Vol. 128, *American Journal Of Orthodontics And Dentofacial Orthopedics.* 2005. P. 442–9. Available From: [Http://Dx.Doi.Org/10.1016/J.Ajodo.2004.05.023](http://Dx.Doi.Org/10.1016/J.Ajodo.2004.05.023)
5. Duraisamy R, Krishnan Cs, Ramasubramanian H, Sampathkumar J, Mariappan S, Navarasampatti Sivaprakasam A. Compatibility Of Nonoriginal Abutments With Implants: Evaluation Of Microgap At The Implant–Abutment Interface, With Original And Nonoriginal Abutments. *Implant Dent.* 2019 Jun;28(3):289.
6. Selvan Sr, Ganapathy D. Efficacy Of Fifth Generation Cephalosporins Against Methicillin-Resistant *Staphylococcus Aureus*-A Review. *Research Journal Of Pharmacy And Technology.* 2016;9(10):1815–8.
7. Kazis H, Kazis Aj. Complete Mouth Rehabilitation Through Fixed Partial Denture Prosthodontics [Internet]. Vol. 10, *The Journal Of Prosthetic Dentistry.* 1960. P. 296–303. Available From: [Http://Dx.Doi.Org/10.1016/0022-3913\(60\)90057-3](http://Dx.Doi.Org/10.1016/0022-3913(60)90057-3)
8. Ganapathy D, Sathyamoorthy A, Ranganathan H, Murthykumar K. Effect Of Resin Bonded Luting Agents Influencing Marginal Discrepancy In All Ceramic Complete Veneer Crowns. *J Clin Diagn Res.* 2016;10(12):Zc67.
9. Lerner J. A Systematic Approach To Full-Mouth Reconstruction Of The Severely Worn Dentition. *Pract Proced Aesthet Dent.* 2008;20(2):81.
10. Subasree S, Murthykumar K, Others. Effect Of Aloe Vera In Oral Health-A Review. *Research Journal Of Pharmacy And Technology.* 2016;9(5):609–12.
11. Goldman I. The Goal Of Full Mouth Rehabilitation. *J Prosthet Dent.* 1952 Mar 1;2(2):246–51.
12. Ranganathan H, Ganapathy Dm, Jain Ar. Cervical And Incisal Marginal Discrepancy In Ceramic Laminate Veneering Materials: A Sem Analysis. *Contemp Clin Dent.* 2017;8(2):272.
13. Kavitha B, Priyadharshini V, Sivapathasundharam B, Saraswathi Tr. Role Of Genes In Oro-Dental Diseases. *Indian J Dent Res.* 2010 Apr 1;21(2):270.
14. Vijayalakshmi B, Ganapathy D. Medical Management Of Cellulitis [Internet]. Vol. 9, *Research Journal Of Pharmacy And Technology.* 2016. P. 2067. Available From: [Http://Dx.Doi.Org/10.5958/0974-360x.2016.00422.4](http://Dx.Doi.Org/10.5958/0974-360x.2016.00422.4)
15. Thesleff I. The Genetic Basis Of Tooth Development And Dental Defects. *Am J Med Genet.* 2006 Dec 1;140a(23):2530–5.
16. Kolenc-Fusé Fj. Tooth Agenesis: In Search Of Mutations Behind Failed Dental Development. *Med Oral Patol Oral Cir Bucal.* 2004;9(5):390–5.
17. Ganapathy Dm, Kannan A, Venugopalan S. Effect Of Coated Surfaces Influencing Screw Loosening In Implants: A Systematic Review And Meta-Analysis [Internet]. Vol. 8, *World Journal Of Dentistry.* 2017. P. 496–502. Available From: [Http://Dx.Doi.Org/10.5005/Jp-Journals-10015-1493](http://Dx.Doi.Org/10.5005/Jp-Journals-10015-1493)
18. Bencharit S, Border Mb, Mack Cr, Byrd Wc, Wright Jt. Full-Mouth Rehabilitation For A Patient With

- Dentinogenesis Imperfecta: A Clinical Report. *J Oral Implantol.* 2014;40(5):593–600.
19. Khandelwal S, Gupta D, Likhyan L. A Case Of Dentin Dysplasia With Full Mouth Rehabilitation: A 3-Year Longitudinal Study. *International Journal Of Clinical Pediatric Dentistry.* 2014;7(2):119.
  20. Sreedevi S, Sanjeev R, Ephraim R, Joseph M. Interdisciplinary Full Mouth Rehabilitation Of A Patient With Amelogenesis Imperfecta: A Case Report With 8 Years Follow-Up. *Journal Of International Oral Health: Jioh.* 2014;6(6):90.
  21. Ashok V, Suvitha S. Awareness Of All Ceramic Restoration In Rural Population. *Research Journal Of Pharmacy And Technology.* 2016;9(10):1691–3.
  22. Ashok V, Nallaswamy D, Benazir Begum S, Nesappan T. Lip Bumper Prosthesis For An Acromegaly Patient: A Clinical Report. *J Indian Prosthodont Soc.* 2014 Dec 1;14(1):279–82.
  23. Hafeez N, Others. Accessory Foramen In The Middle Cranial Fossa. *Research Journal Of Pharmacy And Technology.* 2016;9(11):1880.
  24. Krishnan Rp, Ramani P, Sherlin Hj, Sukumaran G, Ramasubramanian A, Jayaraj G, Et Al. Surgical Specimen Handover From Operation Theater To Laboratory: A Survey. *Ann Maxillofac Surg.* 2018 Jul;8(2):234–8.
  25. Somasundaram S, Ravi K, Rajapandian K, Gurunathan D. Fluoride Content Of Bottled Drinking Water In Chennai, Tamilnadu. *J Clin Diagn Res.* 2015;9(10):Zc32.
  26. Felicita As, Sumathi Felicita A. Orthodontic Extrusion Of Ellis Class Viii Fracture Of Maxillary Lateral Incisor – The Sling Shot Method [Internet]. Vol. 30, *The Saudi Dental Journal.* 2018. P. 265–9. Available From: [Http://Dx.Doi.Org/10.1016/J.Sdentj.2018.05.001](http://Dx.Doi.Org/10.1016/J.Sdentj.2018.05.001)
  27. Kumar S, Rahman R. Knowledge, Awareness, And Practices Regarding Biomedical Waste Management Among Undergraduate Dental Students. *Asian J Pharm Clin Res.* 2017 Aug 1;10(8):341.
  28. Gurunathan D, Shanmugaavel Ak. Dental Neglect Among Children In Chennai. *J Indian Soc Pedod Prev Dent.* 2016 Oct 1;34(4):364.
  29. Sneha S, Others. Knowledge And Awareness Regarding Antibiotic Prophylaxis For Infective Endocarditis Among Undergraduate Dental Students. *Asian Journal Of Pharmaceutical And Clinical Research.* 2016;154–9.
  30. Dhinesh B, Isaac Joshuaramesh Lalvani J, Parthasarathy M, Annamalai K. An Assessment On Performance, Emission And Combustion Characteristics Of Single Cylinder Diesel Engine Powered By Cymbopogon Flexuosus Biofuel. *Energy Convers Manage.* 2016 Jun 1;117:466–74.
  31. Choudhari S, Thenmozhi Ms. Occurrence And Importance Of Posterior Condylar Foramen. Lateral. *2016;8:11–43.*
  32. Paramasivam A, Vijayashree Priyadharsini J, Raghunandhakumar S. N6-Adenosine Methylation (M6a): A Promising New Molecular Target In Hypertension And Cardiovascular Diseases. *Hypertens Res.* 2020 Feb;43(2):153–4.
  33. Wu F, Zhu J, Li G, Wang J, Veeraghavan Vp, Krishna Mohan S, Et Al. Biologically Synthesized Green Gold Nanoparticles From Siberian Ginseng Induce Growth-Inhibitory Effect On Melanoma Cells (B16). *Artif Cells Nanomed Biotechnol.* 2019 Dec;47(1):3297–305.
  34. Palati S, Ramani P, Shrelin H, Sukumaran G, Ramasubramanian A, Don Kr, Et Al. Knowledge, Attitude And Practice Survey On The Perspective Of Oral Lesions And Dental Health In Geriatric Patients Residing In Old Age Homes [Internet]. Vol. 31, *Indian Journal Of Dental Research.* 2020. P. 22. Available From: [Http://Dx.Doi.Org/10.4103/Ijdr.Ijdr\\_195\\_18](http://Dx.Doi.Org/10.4103/Ijdr.Ijdr_195_18)
  35. Saravanan M, Arokiyaraj S, Lakshmi T, Pugazhendhi A. Synthesis Of Silver Nanoparticles From Phenerochaete Chrysochlorium (Mtcc-787) And Their Antibacterial Activity Against Human Pathogenic Bacteria. *Microb Pathog.* 2018 Apr;117:68–72.
  36. Govindaraju L, Gurunathan D. Effectiveness Of Chewable Tooth Brush In Children-A Prospective Clinical Study. *J Clin Diagn Res.* 2017;11(3):Zc31.
  37. Vijayakumar Jain S, Muthusekhar Mr, Baig Mf, Senthilnathan P, Loganathan S, Abdul Wahab Pu, Et Al. Evaluation Of Three-Dimensional Changes In Pharyngeal Airway Following Isolated Lefort One Osteotomy For The Correction Of Vertical Maxillary Excess: A Prospective Study. *J Maxillofac Oral Surg.* 2019 Mar;18(1):139–46.
  38. Aljeaidi Z. Multidisciplinary Approach To Full Mouth Rehabilitation. *Journal Of Dental Research And Review.* 2016 Jul 1;3(3):103.
  39. Song M-Y, Park J-M, Park E-J. Full Mouth Rehabilitation Of The Patient With Severely Worn Dentition: A Case Report. *J Adv Prosthodont.* 2010;2(3):106–10.
  40. Moslehifard E, Nikzad S, Geraminpanah F, Mahboub F. Full-Mouth Rehabilitation Of A Patient With Severely Worn Dentition And Uneven Occlusal Plane: A Clinical Report. *Journal Of Prosthodontics:*

- Implant, Esthetic And Reconstructive Dentistry. 2012;21(1):56–64.
41. Venugopalan S, Ariga P, Aggarwal P, Viswanath A. Magnetically Retained Silicone Facial Prosthesis [Internet]. Vol. 17, Nigerian Journal Of Clinical Practice. 2014. P. 260. Available From: [Http://Dx.Doi.Org/10.4103/1119-3077.127575](http://Dx.Doi.Org/10.4103/1119-3077.127575)
  42. Kannan A, Venugopalan S. A Systematic Review On The Effect Of Use Of Impregnated Retraction Cords On Gingiva. Research Journal Of Pharmacy And Technology. 2018;11(5):2121–6.
  43. Anuroopa A, Abdulla J, Lovely M. Oral Rehabilitation Of A Young Patient With Hypohidrotic Ectodermal Dysplasia: A Clinical Report. Contemp Clin Dent. 2012;3(Suppl1):S33.
  44. Koyuncuoglu Cz, Metin S, Minoglu-Saylan I, Calisir K, Tuncer O, Alpdogan K. Full-Mouth Rehabilitation Of A Patient With Ectodermal Dysplasia Patient With Dental Implants [Internet]. Journal Of Oral Implantology. 2012. P. 141208072802005. Available From: [Http://Dx.Doi.Org/10.1563/Aaid-Joi-D-12-00072.1](http://Dx.Doi.Org/10.1563/Aaid-Joi-D-12-00072.1)
  45. Atil F, Culhaoglu A, Kocyigit Id, Adisen Z, Misirlioglu M, Yilmaz B. Oral Rehabilitation With Implant-Supported Fixed Dental Prosthesis Of A Patient With Cleidocranial Dysplasia. J Prosthet Dent. 2018 Jan 1;119(1):12–6.
  46. Ribeiro Cg, Siqueira Af, Bez L, Cardoso Ac, Ferreira Cf. Dental Implant Rehabilitation Of A Patient With Down Syndrome: A Case Report. J Oral Implantol. 2011;37(4):481–7.
  47. Vijayashree Priyadharsini J. In Silico Validation Of The Non-Antibiotic Drugs Acetaminophen And Ibuprofen As Antibacterial Agents Against Red Complex Pathogens. J Periodontol. 2019 Dec;90(12):1441–8.
  48. Pc J, Marimuthu T, Devadoss P. Prevalence And Measurement Of Anterior Loop Of The Mandibular Canal Using Cbct: A Cross Sectional Study. Clin Implant Dent Relat Res [Internet]. 2018; Available From: [Https://Europepmc.Org/Article/Med/29624863](https://Europepmc.Org/Article/Med/29624863)
  49. Ramesh A, Varghese S, Jayakumar Nd, Malaiappan S. Comparative Estimation Of Sulfiredoxin Levels Between Chronic Periodontitis And Healthy Patients - A Case-Control Study. J Periodontol. 2018 Oct;89(10):1241–8.
  50. Ramadurai N, Gurunathan D, Samuel Av, Subramanian E, Rodrigues Sjl. Effectiveness Of 2% Articaine As An Anesthetic Agent In Children: Randomized Controlled Trial. Clin Oral Investig. 2019 Sep;23(9):3543–50.
  51. Sridharan G, Ramani P, Patankar S, Vijayaraghavan R. Evaluation Of Salivary Metabolomics In Oral Leukoplakia And Oral Squamous Cell Carcinoma. J Oral Pathol Med. 2019 Apr;48(4):299–306.
  52. Ezhilarasan D, Apoorva Vs, Ashok Vardhan N. Syzygium Cumini Extract Induced Reactive Oxygen Species-Mediated Apoptosis In Human Oral Squamous Carcinoma Cells. J Oral Pathol Med. 2019 Feb;48(2):115–21.
  53. Mathew Mg, Samuel Sr, Soni Aj, Roopa Kb. Evaluation Of Adhesion Of Streptococcus Mutans, Plaque Accumulation On Zirconia And Stainless Steel Crowns, And Surrounding Gingival Inflammation In Primary Molars: Randomized Controlled Trial. Clin Oral Investig. 2020;1–6.
  54. Samuel Sr. Can 5-Year-Olds Sensibly Self-Report The Impact Of Developmental Enamel Defects On Their Quality Of Life? Int J Paediatr Dent. 2021 Mar;31(2):285–6.
  55. R H, Hannah R, Ramani P, Ramanathan A, R Jm, Gheena S, Et Al. Cyp2 C9 Polymorphism Among Patients With Oral Squamous Cell Carcinoma And Its Role In Altering The Metabolism Of Benzo[A]Pyrene [Internet]. Vol. 130, Oral Surgery, Oral Medicine, Oral Pathology And Oral Radiology. 2020. P. 306–12. Available From: [Http://Dx.Doi.Org/10.1016/J.Oooo.2020.06.021](http://Dx.Doi.Org/10.1016/J.Oooo.2020.06.021)
  56. Chandrasekar R, Chandrasekhar S, Sundari Kks, Ravi P. Development And Validation Of A Formula For Objective Assessment Of Cervical Vertebral Bone Age. Prog Orthod. 2020 Oct 12;21(1):38.
  57. Vijayashree Priyadharsini J, Smiline Girija As, Paramasivam A. In Silico Analysis Of Virulence Genes In An Emerging Dental Pathogen A. Baumannii And Related Species. Arch Oral Biol. 2018 Oct;94:93–8.
  58. Basha Fys, Ganapathy D, Venugopalan S. Oral Hygiene Status Among Pregnant Women. Research Journal Of Pharmacy And Technology. 2018;11(7):3099–102.
  59. Ajay R, Suma K, Ali S, Sivakumar Jk, Rakshagan V, Devaki V, Et Al. Effect Of Surface Modifications On The Retention Of Cement-Retained Implant Crowns Under Fatigue Loads: An In Vitro Study [Internet]. Vol. 9, Journal Of Pharmacy And Bioallied Sciences. 2017. P. 154. Available From: [Http://Dx.Doi.Org/10.4103/Jpbs.Jpbs\\_146\\_17](http://Dx.Doi.Org/10.4103/Jpbs.Jpbs_146_17)

**Legends:**

**Tables :**

Table 1: Descriptive Distribution Of Various Genetic Disorder Cases Reported At Saveetha Dental College.

**Figures :**

Figure 1: Descriptive Distribution Of Total Number Of Cases Reported For Full Mouth Rehabilitation And Its Association With The Patients In Different Age Groups.

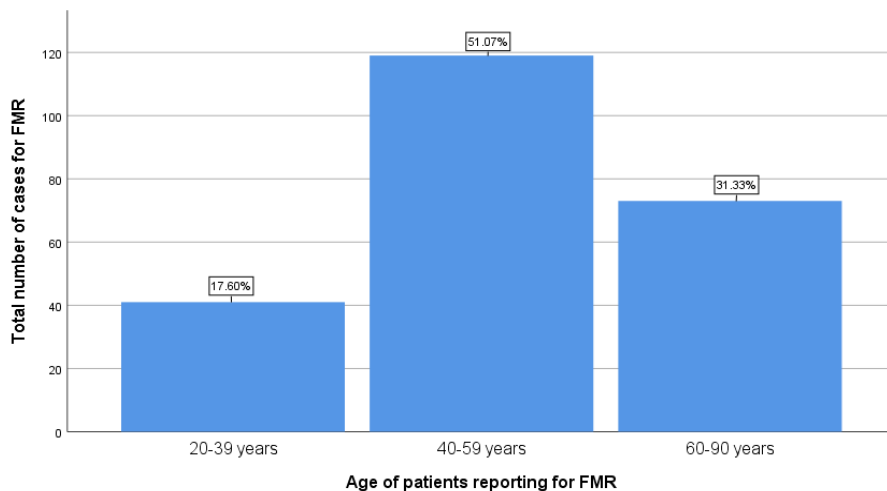
Figure 2: Descriptive Distribution Of The Total Number Of Full Mouth Rehabilitation Cases Treated In A University Setting.

Figure 3: Descriptive Distribution Of The Total Number Of Genetic Disorder Cases Reported For Full Mouth Rehabilitation In A University Setting.

Figure 4: Graphical Representation Of Total Number Of Genetic Disorder Cases And Total Full Mouth Rehabilitation Cases.

Genetic Disorder	Count
Congenital Hydrocephalus Schizencephaly	1
Autism	1
Ectodermal Dysplasia	2
Downs Syndrome	1
Cleidocranial Dysplasia	1
Parkinson’s Disease	1
Idiopathic/ Familial Pulmonary Fibrosis	1
Irritable Bowel Syndrome	1

Table 1: Descriptive Distribution Of Various Genetic Disorder Cases Reported In A University Setting.



## Full Mouth Rehabilitation In Genetic Disorder Patients- A Retrospective Study

Figure 1: Bar Graph Showing Total Number Of Cases Reported For Full Mouth Rehabilitation And Its Association With The Patients In Different Age Groups. X Axis Represents The Age Distribution Of The Patients Reporting For Fmr And Y Axis Represents The Total Number Of Cases In Each Age Group Reporting For Fmr. The Maximum Fmr Cases Were Seen In The Age Group 40-59 Years (51.07%) .

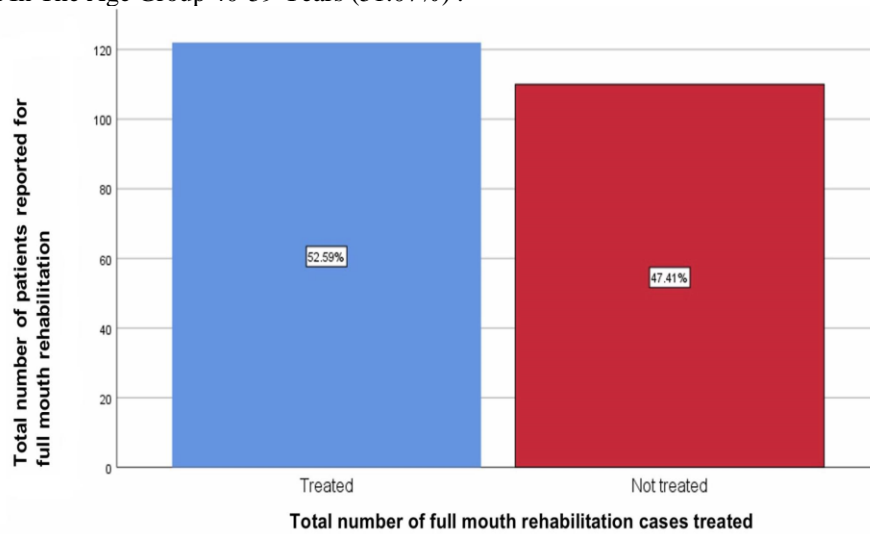


Figure 2: Bar Graph Showing Total Number Of Full Mouth Rehabilitation Cases Treated In A University Setting. X Axis Represents The Number Of Cases Treated And Untreated By Fmr And Y Axis Represents The Total Number Of Patients Reporting For Fmr. Blue Denotes The Number Of Cases Treated By Fmr Which Is 123 (52.59%) And Red Denotes The Number Of Cases Not Treated By Fmr 110 (47.41%) As Patients Were Not Willing For Treatment. Therefore There Is An Increased Number Of Cases Required To Be Treated By Fmr.

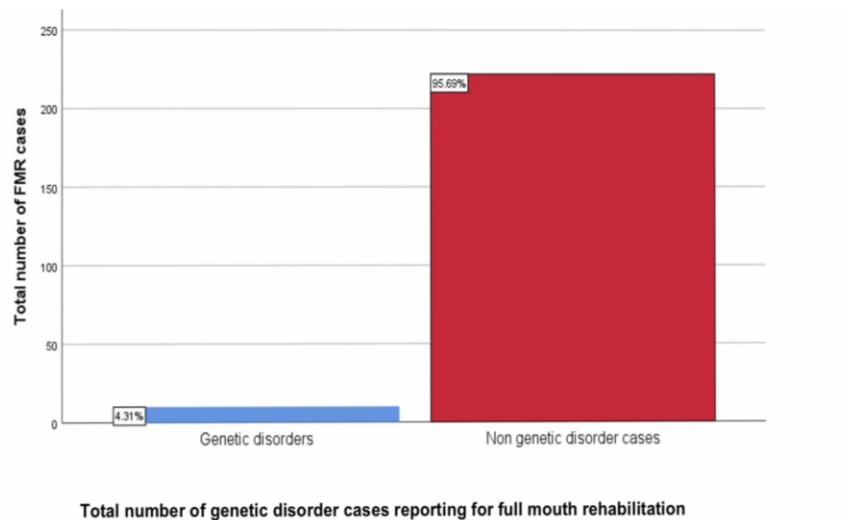


Figure 3: Bar Graph Showing Total Number Of Genetic Disorder Cases Reported For Full Mouth Rehabilitation In A University Setting. X Axis Represents The Number Of Genetic Disorder Cases Reporting For Fmr And Y Axis Represents The Total Number Of Patients Reporting For Fmr. Blue Denotes The Number Of Genetic Disorder Cases Treated By Fmr Which Is 9 (4.31%) And Red Denotes Non-Genetic Disorder Cases Treated By Fmr Which Is 224 (95.69%). This Shows That Genetic Disorder Cases Reporting In A University Setting Is Comparatively Lesser.



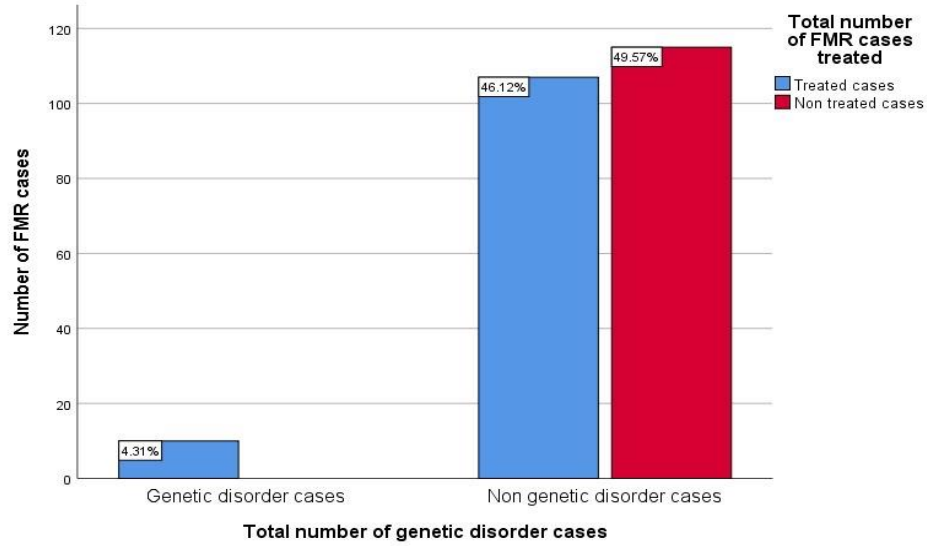


Figure 4: Graphical Representation Of Total Number Of Genetic Disorder Cases And Total Full Mouth Rehabilitation Cases. X Axis Represents The Number Of Genetic And Non Genetic Disorder Cases Treated With Fmr And Y Axis Represents The Number Of Fmr Cases. Blue Bars Represent The Number Of Cases Treated With Fmr And Red Bars Represent The Number Of Cases Not Treated With Fmr. Majority Of The Non Genetic Disorder Cases With (46.12%) Were Treated With Fmr As Compared To Genetic Disorder Cases With (4.31%). There Is A Significant Difference Between Genetic And Non Genetic Disorder Cases Treated. Chi Square Test Was Done And Association Was Statistically Significant. Chi Square Test Value: 10.272 ,P Value: 0.001, P Value <0.05.