

## **Incidence Of Perforation Repair In Maxillary Molars With Furcation Involvement - A Retrospective Study**

### **Roghith Kannan**

Saveetha Dental College And Hospitals,  
Saveetha Institute Of Medical And Technical Sciences (Simats),  
Saveetha University,  
Chennai, India  
Email Id: [151501083.Sdc@Saveetha.Com](mailto:151501083.Sdc@Saveetha.Com)

### **Adimulapu Hima Sandeep**

Senior Lecturer, Department Of Conservative Dentistry And Endodontics,  
Saveetha Dental College And Hospitals,  
Saveetha Institute Of Medical And Technical Sciences (Simats),  
Saveetha University,  
Chennai, India, Email Id: [Himas.Sdc@Saveetha.Com](mailto:Himas.Sdc@Saveetha.Com)

### **Revathi Duraisamy**

Senior Lecturer,  
Department Of Prosthodontics,  
Saveetha Dental College And Hospitals,  
Saveetha Institute Of Medical And Technical Sciences (Simats),  
Saveetha University,  
Chennai, India  
Email Id: [Revathid.Sdc@Saveetha.Com](mailto:Revathid.Sdc@Saveetha.Com)

### **Abstract :**

One Of The Most Frequent Iatrogenic Mishaps During Root Canal Treatment Of Posterior Teeth Is Perforation Of The Pulpal Floor During Access Opening/Biomechanical Preparation. It Leads To An Open Communication Between The Root Canal System And The Supporting Tissues Of The Tooth Leading To Formation Of Serous Exudates, Sinus At The Site Of Perforation If Left Untreated. The Development Of Different Techniques And Newer Materials Has Led To Success In Perforation Repairs. The Main Objective Of This Study Was To Evaluate Perforation Repair In Furcal Involving Maxillary Molars In Patients Under 50 Years Of Age. The Current Study Is An Institutional Based Retrospective Study Performed Over Reviewing 86,000 Case Records. A Total Of 14 Subjects Who Underwent Furcal Perforation Repair In Relation To Maxillary Molars Under 50 Years Of Age Were Chosen For The Study Out Of 6475 Subjects Who Had Undergone Root Canal Treatment In Various Teeth. Patients With Other Than Perforation Repairs And Medically Compromised Were Excluded. Once The Data Was Obtained, Analysis Was Done By Descriptive And Inferential Statistics Using Spss By Ibm Version 20. From This Current Study, It Was Found That, Out Of 14 Patients, 9 Males(64.29%) And 5 Females(35.71%) Have Undergone Perforation Repair Treatment. Highest Incidence Of Perforation Repair Was Seen In Tooth Number 26 (42.86%). Patients In The Age Group Of 41-50 Years Had The Highest Incidence Of Perforation Repair In Relation To Maxillary Molars. Adequate Knowledge, Experience And Clinical Skill Enables Good Management Of Furcal Perforations.

### **Keywords :**

Furcation , Maxillary, Molars, Perforation Repair

### **Introduction:**

The Variations In Root Canal Anatomy Of Multirouted Teeth Are A Constant Challenge For Diagnosis And Successful Endodontic Management. The Maxillary Molar Has Been Reported With Various Root Canal Anatomy Having Four Roots [1], Two Roots, And Even A Single Root With A Single Canal[2]. The Prevalence Of A Single Canal In The Maxillary Molar Is Reported To Be 0.5-0.6% [3]. Furcal Perforation Consists Of Communication Between The Pulp Cavity And The Periodontal Tissues. They Are One Of The Most Challenging Causes Of Endodontic Failures [4]. This Complication May Be Caused By Iatrogenic Or Non Iatrogenic Factors And Can Occur In Permanent As Well As Primary Teeth. Iatrogenic Causes Include Perforation During Either Access Opening Or During Root Canal Instrumentation, While The Non Iatrogenic Factors Include Progressive Internal Resorption Or Caries Process Development [5]. Calcification Of The Pulp Chamber And The Orifices, Misidentification Of The Canals, Significant Crown-Root Angulations And Excessive Removal Of Coronal Dentin Can Easily Result In Perforation Of The Coronal Or Furcation Regions. Strip Perforation Of The Middle Third May Occur If There Is Overzealous Instrumentation [6]. The Consequences Of The Perforation Depends On The Size, Location And Period Of Impairment, Leading To Inflammatory Reactions And Compromising The Periodontal Tissue Irreversibly, Resulting In Tooth Loss [7].

Diagnosis Of The Perforations Are Important. If Left Undiagnosed, It Can Lead To Further Complications [8]. Iatrogenic Perforations Are Invariably Identified By The Profuse Bleeding That Follows By The Injury. Apex Locators Are Also Very Useful In Detecting The Perforations. Late Diagnosis Of The Pathological Perforations Is Largely A Combination Of Clinical Assessment, Nature Of The Presenting Complaint And Radiographs. Untreated Perforations May Be Revealed By The Presence Of Serous Exudates Or Sinus From The Site Of Perforation, Severity To The Periodontium And Chronic Inflammation[9].

Therefore Either Sealing The Perforated Site With A Biocompatible Material Or By Using Surgical Technique Is Necessary To Promote The Repair Of The Perforated Area. Several Materials Have Been Suggested For Repair Of Furcal Perforations Such As Amalgam, Gutta Percha, Cavit, Composite Resin, Mta, Glass Ionomer Cement, Calcium Hydroxide [10,11] [12]. The Ideal Material Should Be Non-Toxic And Biocompatible In Order To Have A Good Outcome. Pro Root Mta Has An Alkaline Ph Of 5 And Studies Have Shown That Its Performance In Microleakage Protection Is Superior To Amalgam, Irm And Biodentine [13]. It Is Biocompatible And Thus Considered An Ideal Material For Conservative Treatment Of Furcal Perforations [14]. Previously Our Team Has A Rich Experience In Working On Various Research Projects Across Multiple Disciplines The [15–17][18–29].

The Frequency Of Furcal Perforation Has Been Reported To Range From 3% To As High As 10% [30]. However As Complex Endodontic Procedures Are Being Performed, There Is Likely A High Chance In The Increase Of The Perforation Percentage In The Future. The Purpose Of This Study Was To Evaluate The Incidence Of Perforation Repair In Furcation Involving Maxillary Molars In Patients Under 50 Years Of Age Based On Institutional Dental Records.

### **Materials And Methods:**

#### **Study Setting**

The Current Study Is An Institutional Based Retrospective Study Performed At A Private Dental College.

#### **Ethical Approval**

The Necessary Approvals Were Obtained From The Institutional Ethical Committee - Sdc/Sihhec/2020/Diasdata/0619-0320.

#### **Data Collection And Tabulation**

## Incidence Of Perforation Repair In Maxillary Molars With Furcation Involvement - A Retrospective Study

All The Case Records And Treatment Records Were Obtained From The Patient Management Software And The Data Collected Was Cross Verified By An Examiner To Avoid Any Missing Case Records. A Total Of 86,000 Case Sheets Were Verified For Root Canal Treatment Data And In Which 6475 Subjects Have Undergone Root Canal Treatment In Various Teeth. Out Of 6475 Cases, 14 Subjects Who Underwent Perforation Repair In Relation To Maxillary Molar Under 50 Years Of Age Were Chosen Carefully Verifying The Data And History. All The Data Collected Was Formatted And Tabulated Using Microsoft Excel (Version - 2020). The Dependent Variable Was Furcal Perforation During Endodontic Therapy.

### **Inclusion Criteria**

The Inclusion Criteria Was Patients Under 50 Years Undergoing Root Canal Treatment With Furcal Perforation In Relation To Maxillary Molars

### **Exclusion Criteria**

The Exclusion Criteria Was Missing Or Incomplete Data And Also Eliminated Cases That Were Not Approved By The Concerned Faculty In The Hospital.

### **Statistical Analysis**

The Statistical Analysis Was Performed Using Ibm Spss (Version - 24). Descriptive Statistics Was Performed To Present The Age Distribution, Gender Distribution Of Patients And The Tooth Involved. Chi Square Test Was Done, To Associate Between Age Groups And Tooth Groups.

### **Results:**

In The Present Study Which Included 14 Patients, 64.29% (9) Males And 35.71% (5) Females Have Undergone Perforation Repair In Relation To Maxillary Molars (Figure 1). The Most Common Tooth Group With Furcal Perforation And Repair Was Found To Be In 26 (42.86%), Which Was Followed By 16 (28.57%) And The Least Being Both 17 And 27 (14.29%) (Figure 2). Out Of 14 Patients Who Had Undergone Perforation Repair In Relation To Maxillary Molars, The Age Group Commonly Identified Were Of 41-50 Years (57.14%) , Which Was Followed By 31-40 Years (28.57%) And The Least Being In The Age Group Of 20-30 Years (14.29%) (Figure 3). Patients In The Age Group Of 41-50 Years, The Frequency Of Perforation Repairs Seen In 26 Was (14.29%), 16 (14.29%) , 17 And 27 (7.14%). Patients In The Age Group Of 31-40 Years, The Frequency Of Perforation Repairs Seen In 16, 17, 26, 27 Was ( 7.14%). Patients In The Age Group Of 20-30 Years, The Frequency Of Perforation Repairs Were Seen In 16 And 26 With (7.14%) . Results Show The Highest Incidence Of Perforation Repairs Was Seen In The Age Group Of 41-50 Years In 26 (28.57%) Compared To Other Age Groups (Figure 4). No Significant Association Was Seen Between Age Groups Andtooth Groups. Chi-Square Test Was Performed And Was Found To Be Statistically Not Significant ( $P = 0.916$ ;  $P > 0.05$ ).

### **Discussion:**

Perforation Sealing Is A Fundamental Treatment To Avoid Tooth Loss, As It Eliminates Or Prevents Inflammatory Reaction Around Adjacent Tissues And Consequent Bone Resorption, Swelling, Suppuration And Pain [31]. From The Results Obtained In This Study, 64.29% Of Males And 35.71% Of Females Had Undergone Perforation Repair In Relation To Maxillary Molars Under 50 Years Of Age Of Which The Most Common Teeth For Perforation Repair Was Found To Be 26 (42.9%). It Was Also Seen That Patients In The Age Group Of 41-50 Years Had The Highest Incidence For Undergoing Perforation Repair.

Besides Effective Perforation Sealing, There Are Other Factors That May Influence The Success Rate Of The Treatment, Such As The Size Of The Perforation, Extensive Internal And Per-Operative Radiolucent Lines Adjacent To The Perforation. In A Study Conducted By Kvinnsland Et Al., 53% Of Furcal Perforations Occur During Insertion Of Posts, The Remaining Occur During Routine Endodontic Procedures [32]. In Multi Rooted Teeth, Furcation Perforations May Occur Whilst Searching For The Canal Orifices, As The Dentin Is Removed From The Pulpal Floor.

Late Diagnosis And Sealing Treatment, Seems To Induce Unfavorable Diagnosis. Delay In Perforation Sealing Impairs The Repair By Increasing The Risk Of Contamination. However The Immediate Sealing Of The Perforation Using Biocompatible Material Reveals Clinical And Radiographic Success. Due To The Paucity Of Reports Evaluating Long Term Clinical Outcomes In Furcal Perforations, Evidence Based Data Are Not Available Yet For Support[33].

Perforation Repair Requires Proper Knowledge Regarding The Size, Site, Time And Various Materials That Are Used Thereby To Achieve A Long Term Success Of The Perforated Tooth. However When The Perforation Is Located On The Buccal Or Palatal Aspect, The Radiographic Tool Becomes A Scarce Diagnostic Aid. The Use Of Apex Locators Help To Accurately Determine The Location Of The Root Perforations, Making Them More Reliable Than The Radiographs. Dental Operating Microscopes Enhance The Visibility Of Perforation In A Magnified Field. It Helps In Locating Even Smaller Perforation Sites So That It Can Be Treated Earlier, Preventing Future Infection [34]. Stem Cell Based Tissue Regeneration For Furcation Repair And Through Biomimetic Approach, It Will Have The Potential To Open A New Era And Strategy In Endodontic Tissue Engineering Therapy [35,36]. Our Institution Is Passionate About High Quality Evidence Based Research And Has Excelled In Various Fields ( [37–47].

### **Conclusion:**

Within The Limitations Of The Study, It Was Concluded That Perforation Repair In Furcal Involving Maxillary Molars Were Identified Most Commonly In Tooth Number 26. Among The Patients Who Had Perforation Repair, Majority Of The Patients Were Male Patients And Patients In The Age Group Of 41-50 Years. The Age Of The Patient Did Not Influence The Tooth Involved In Perforation Repair. With Regards To The Instrumentation, Knowledge About The Anatomy Should Be Taken Into Consideration In Order To Prevent Procedural Mishaps. The Development In Technology, Advanced Armamentarium, And Expertise Enable Successful Management Of Furcal Perforations.

### **Author Contribution**

Roghith Kannan Carried Out The Retrospective Study, Collection And Analysis Of Data And Drafted The Manuscript. Dr Adimulapu Hima Sandeep Designed The Study And Participated In Data Analysis Verification And Drafting The Manuscript. Dr Revathi D Aided In Supervision And Appraisal Of The Manuscript.

### **Acknowledgements**

We Thank Saveetha Dental College And Hospitals, Chennai For Giving Access To The Retrospective Data And Case Records.

### **Conflict Of Interest**

No Conflict Of Interest

### **References:**

- [1] Libfeld H, Rotstein I. Incidence Of Four-Rooted Maxillary Second Molars: Literature Review And Radiographic Survey Of 1,200 Teeth. *Journal Of Endodontics* 1989;15:129–31. [https://doi.org/10.1016/S0099-2399\(89\)80134-7](https://doi.org/10.1016/S0099-2399(89)80134-7).
- [2] Deveaux E. Maxillary Second Molar With Two Palatal Roots. *Journal Of Endodontics* 1999;25:571–3. [https://doi.org/10.1016/S0099-2399\(99\)80383-5](https://doi.org/10.1016/S0099-2399(99)80383-5).
- [3] Hartwell G, Bellizzi R. Clinical Investigation Of In Vivo Endodontically Treated Mandibular And Maxillary Molars. *Journal Of Endodontics* 1982;8:555–7. [https://doi.org/10.1016/S0099-2399\(82\)80016-2](https://doi.org/10.1016/S0099-2399(82)80016-2).
- [4] Fuss Z, Trope M. Root Perforations: Classification And Treatment Choices Based On Prognostic Factors. *Dental Traumatology* 1996;12:255–64. <https://doi.org/10.1111/J.1600-9657.1996.Tb00524.X>.
- [5] Seltzer S, Bender Ib, Smith J, Freedman I, Nazimov H. Endodontic Failures—An Analysis Based On Clinical,

- Roentgenographic, And Histologic Findings. *Oral Surgery, Oral Medicine, Oral Pathology* 1967;23:517–30. [https://doi.org/10.1016/0030-4220\(67\)90547-6](https://doi.org/10.1016/0030-4220(67)90547-6).
- [6] Ibarrola JI, Biggs Sg, Beeson Tj. Repair Of A Large Furcation Perforation: A Four-Year Follow-Up. *Journal Of Endodontics* 2008;34:617–9. <https://doi.org/10.1016/j.joen.2008.01.017>.
- [7] Seltzer S, Sinai I, August D. Periodontal Effects Of Root Perforations Before And During Endodontic Procedures. *Journal Of Dental Research* 1970;49:332–9. <https://doi.org/10.1177/00220345700490022301>.
- [8] Tsesis I, Fuss Z. Diagnosis And Treatment Of Accidental Root Perforations. *Endodontic Topics* 2006;13:95–107. <https://doi.org/10.1111/j.1601-1546.2006.00213.x>.
- [9] Waerhaug J. The Furcation Problem. Etiology, Pathogenesis, Diagnosis, Therapy And Prognosis. *Journal Of Clinical Periodontology* 1980;7:73–95. <https://doi.org/10.1111/j.1600-051x.1980.tb01951.x>.
- [10] Alghamdi F, Aljahdali E. Comparison Of Mineral Trioxide Uggregate, Endosequence Root Repair Material, And Biodentine Used For Repairing Root Perforations: A Systematic Review. *Cumhuriyet Dental Journal* 2019;469–76. <https://doi.org/10.7126/Cumudj.589413>.
- [11] Arens De, Torabinejad M. Repair Of Furcal Perforations With Mineral Trioxide Aggregate. *Oral Surgery, Oral Medicine, Oral Pathology, Oral Radiology, And Endodontology* 1996;82:84–8. [https://doi.org/10.1016/S1079-2104\(96\)80382-9](https://doi.org/10.1016/S1079-2104(96)80382-9).
- [12] Asgary S. Furcal Perforation Repair Using Calcium Enriched Mixture Cement. *Journal Of Conservative Dentistry* 2010;13:156. <https://doi.org/10.4103/0972-0707.71650>.
- [13] Comparative Evaluation Of Sealing Ability Of Proroot Mta, Biodentine, And Bone Cement In The Repair Of Furcation Perforation – An In Vitro Study. *Indian Journal Of Dental Advancements* 2019;10. <https://doi.org/10.5866/2018.10.10176>.
- [14] Vajrabhaya L-O, Korsuwannawong S, Jantarat J, Korre S. Biocompatibility Of Furcal Perforation Repair Material Using Cell Culture Technique: Ketac Molar Versus Proroot Mta. *Oral Surgery, Oral Medicine, Oral Pathology, Oral Radiology, And Endodontology* 2006;102:E48–50. <https://doi.org/10.1016/j.tripleo.2006.05.015>.
- [15] Hafeez N, Others. Accessory Foramen In The Middle Cranial Fossa. *Research Journal Of Pharmacy And Technology* 2016;9:1880.
- [16] Krishnan Rp, Ramani P, Sherlin Hj, Sukumaran G, Ramasubramanian A, Jayaraj G, Et Al. Surgical Specimen Handover From Operation Theater To Laboratory: A Survey. *Ann Maxillofac Surg* 2018;8:234–8.
- [17] Somasundaram S, Ravi K, Rajapandian K, Gurunathan D. Fluoride Content Of Bottled Drinking Water In Chennai, Tamilnadu. *J Clin Diagn Res* 2015;9:Zc32.
- [18] Felicita As, Sumathi Felicita A. Orthodontic Extrusion Of Ellis Class Viii Fracture Of Maxillary Lateral Incisor – The Sling Shot Method. *The Saudi Dental Journal* 2018;30:265–9. <https://doi.org/10.1016/j.sdentj.2018.05.001>.
- [19] Kumar S, Rahman R. Knowledge, Awareness, And Practices Regarding Biomedical Waste Management Among Undergraduate Dental Students. *Asian J Pharm Clin Res* 2017;10:341.
- [20] Gurunathan D, Shanmugaavel Ak. Dental Neglect Among Children In Chennai. *J Indian Soc Pedod Prev Dent* 2016;34:364.
- [21] Sneha S, Others. Knowledge And Awareness Regarding Antibiotic Prophylaxis For Infective Endocarditis Among Undergraduate Dental Students. *Asian Journal Of Pharmaceutical And Clinical Research* 2016:154–9.
- [22] Dhinesh B, Isaac Joshuaramesh Lalvani J, Parthasarathy M, Annamalai K. An Assessment On Performance, Emission And Combustion Characteristics Of Single Cylinder Diesel Engine Powered By Cymbopogon Flexuosus Biofuel. *Energy Convers Manage* 2016;117:466–74.
- [23] Choudhari S, Thenmozhi Ms. Occurrence And Importance Of Posterior Condylar Foramen. *Laterality* 2016;8:11–43.
- [24] Paramasivam A, Vijayashree Priyadharsini J, Raghunandhakumar S. N6-Adenosine Methylation (M6a): A Promising New Molecular Target In Hypertension And Cardiovascular Diseases. *Hypertens Res* 2020;43:153–4.
- [25] Wu F, Zhu J, Li G, Wang J, Veeraraghavan Vp, Krishna Mohan S, Et Al. Biologically Synthesized Green Gold Nanoparticles From Siberian Ginseng Induce Growth-Inhibitory Effect On Melanoma Cells (B16). *Artif Cells Nanomed Biotechnol* 2019;47:3297–305.
- [26] Palati S, Ramani P, Shrelin H, Sukumaran G, Ramasubramanian A, Don Kr, Et Al. Knowledge, Attitude And Practice Survey On The Perspective Of Oral Lesions And Dental Health In Geriatric Patients Residing In Old Age Homes. *Indian Journal Of Dental Research* 2020;31:22. [https://doi.org/10.4103/ijdr.ijdr\\_195\\_18](https://doi.org/10.4103/ijdr.ijdr_195_18).
- [27] Saravanan M, Arokiyaraj S, Lakshmi T, Pugazhendhi A. Synthesis Of Silver Nanoparticles From

- Phenerochaete Chryso sporium (Mtcc-787) And Their Antibacterial Activity Against Human Pathogenic Bacteria. *Microb Pathog* 2018;117:68–72.
- [28] Govindaraju L, Gurnathan D. Effectiveness Of Chewable Tooth Brush In Children-A Prospective Clinical Study. *J Clin Diagn Res* 2017;11:Zc31.
- [29] Vijayakumar Jain S, Muthusekhar Mr, Baig Mf, Senthilnathan P, Loganathan S, Abdul Wahab Pu, Et Al. Evaluation Of Three-Dimensional Changes In Pharyngeal Airway Following Isolated Lefort One Osteotomy For The Correction Of Vertical Maxillary Excess: A Prospective Study. *J Maxillofac Oral Surg* 2019;18:139–46.
- [30] Samiee M, Eghbal Mj, Parirokh M, Abbas Fm, Asgary S. Repair Of Furcal Perforation Using A New Endodontic Cement. *Clinical Oral Investigations* 2010;14:653–8. <https://doi.org/10.1007/S00784-009-0351-8>.
- [31] Kratchman Si. Perforation Repair And One-Step Apexification Procedures. *Dental Clinics Of North America* 2004;48:291–307. <https://doi.org/10.1016/J.Cden.2003.12.003>.
- [32] Kvinnsland I, Oswald Rj, Halse A, Grønningsæter Ag. A Clinical And Roentgenological Study Of 55 Cases Of Root Perforation. *International Endodontic Journal* 1989;22:75–84. <https://doi.org/10.1111/J.1365-2591.1989.Tb00509.X>.
- [33] Alhadainy Ha, Himel Vt, Boyed Lee W, Elbaghdady Ym. Use Of A Hydroxylapatite-Based Material And Calcium Sulfate As Artificial Floors To Repair Furcal Perforations. *Oral Surgery, Oral Medicine, Oral Pathology, Oral Radiology, And Endodontology* 1998;86:723–9. [https://doi.org/10.1016/S1079-2104\(98\)90211-6](https://doi.org/10.1016/S1079-2104(98)90211-6).
- [34] Kopper Pp, Schmidt B, Zaccara I, Só Mr, Kuga M, Palma-Dibb R. Influence Of Operating Microscope In The Sealing Of Cervical Perforations. *Journal Of Conservative Dentistry* 2016;19:152. <https://doi.org/10.4103/0972-0707.178695>.
- [35] Bakhtiar H, Mirzaei H, Bagheri Mr, Fani N, Mashhadiabbas F, Baghaban Eslaminejad M, Et Al. Histologic Tissue Response To Furcation Perforation Repair Using Mineral Trioxide Aggregate Or Dental Pulp Stem Cells Loaded Onto Treated Dentin Matrix Or Tricalcium Phosphate. *Clinical Oral Investigations* 2017;21:1579–88. <https://doi.org/10.1007/S00784-016-1967-0>.
- [36] Sanz M, Jepsen K, Eickholz P, Jepsen S. Clinical Concepts For Regenerative Therapy In Furcations. *Periodontology* 2000 2015;68:308–32. <https://doi.org/10.1111/Prd.12081>.
- [37] Vijayashree Priyadharsini J. In Silico Validation Of The Non-Antibiotic Drugs Acetaminophen And Ibuprofen As Antibacterial Agents Against Red Complex Pathogens. *J Periodontol* 2019;90:1441–8.
- [38] Pc J, Marimuthu T, Devadoss P. Prevalence And Measurement Of Anterior Loop Of The Mandibular Canal Using Cbct: A Cross Sectional Study. *Clin Implant Dent Relat Res* 2018.
- [39] Ramesh A, Varghese S, Jayakumar Nd, Malaiappan S. Comparative Estimation Of Sulfiredoxin Levels Between Chronic Periodontitis And Healthy Patients - A Case-Control Study. *J Periodontol* 2018;89:1241–8.
- [40] Ramadurai N, Gurnathan D, Samuel Av, Subramanian E, Rodrigues Sjl. Effectiveness Of 2% Articaine As An Anesthetic Agent In Children: Randomized Controlled Trial. *Clin Oral Investig* 2019;23:3543–50.
- [41] Sridharan G, Ramani P, Patankar S, Vijayaraghavan R. Evaluation Of Salivary Metabolomics In Oral Leukoplakia And Oral Squamous Cell Carcinoma. *J Oral Pathol Med* 2019;48:299–306.
- [42] Ezhilarasan D, Apoorva Vs, Ashok Vardhan N. Syzygium Cumini Extract Induced Reactive Oxygen Species-Mediated Apoptosis In Human Oral Squamous Carcinoma Cells. *J Oral Pathol Med* 2019;48:115–21.
- [43] Mathew Mg, Samuel Sr, Soni Aj, Roopa Kb. Evaluation Of Adhesion Of Streptococcus Mutans, Plaque Accumulation On Zirconia And Stainless Steel Crowns, And Surrounding Gingival Inflammation In Primary Molars: Randomized Controlled Trial. *Clin Oral Investig* 2020:1–6.
- [44] Samuel Sr. Can 5-Year-Olds Sensibly Self-Report The Impact Of Developmental Enamel Defects On Their Quality Of Life? *Int J Paediatr Dent* 2021;31:285–6.
- [45] R H, Hannah R, Ramani P, Ramanathan A, R Jm, Gheena S, Et Al. Cyp2 C9 Polymorphism Among Patients With Oral Squamous Cell Carcinoma And Its Role In Altering The Metabolism Of Benzo[A]Pyrene. *Oral Surgery, Oral Medicine, Oral Pathology And Oral Radiology* 2020;130:306–12. <https://doi.org/10.1016/J.Oooo.2020.06.021>.
- [46] Chandrasekar R, Chandrasekhar S, Sundari Kks, Ravi P. Development And Validation Of A Formula For Objective Assessment Of Cervical Vertebral Bone Age. *Prog Orthod* 2020;21:38.
- [47] Vijayashree Priyadharsini J, Smiline Girija As, Paramasivam A. In Silico Analysis Of Virulence Genes In An Emerging Dental Pathogen *A. Baumannii* And Related Species. *Arch Oral Biol* 2018;94:93–8.

Figures:

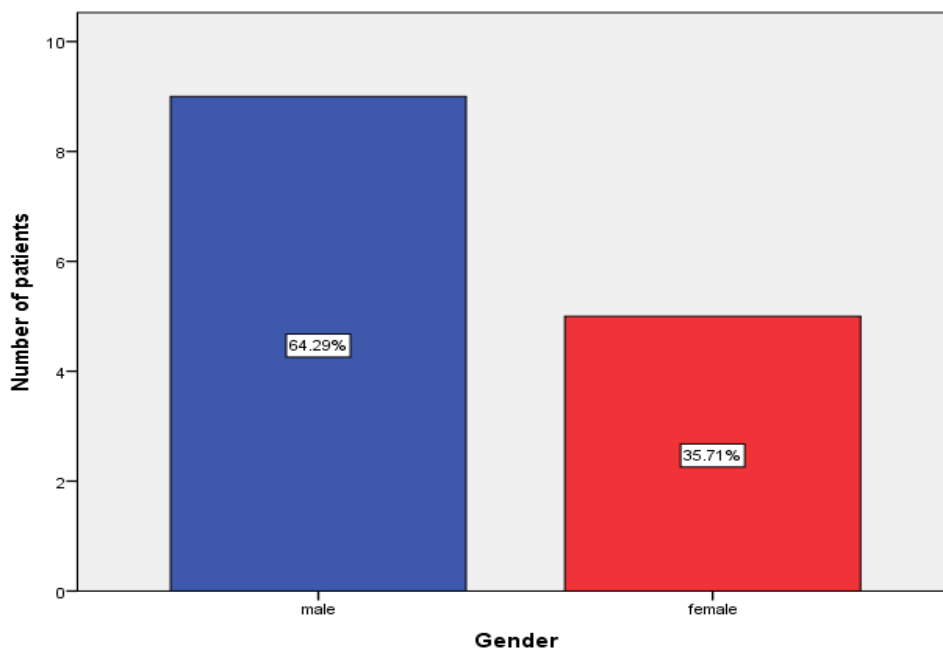


Figure 1: Bar Graph Depicts The Frequency Of Males And Females Who Had Undergone Perforation Repair In Relation To Maxillary Molars. X Axis Represents The Gender Of Patients And Y Axis Shows The Number Of Patients Undergone Perforation Repair. The Results Show The Highest Number Subjected To Perforation Repair In Relation To Maxillary Molars Was Seen In Males (Blue) 64.29% Compared To Females (Red) 35.71%.

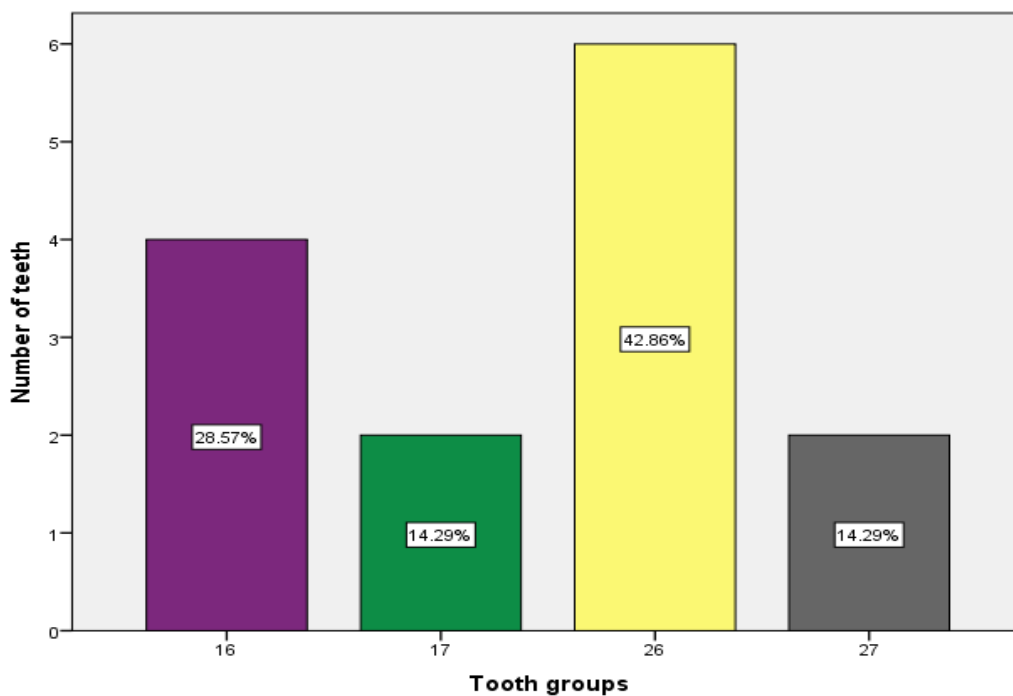


Figure 2: Bar Graph Depicts The Frequency Of Various Tooth Groups Involved In Perforation Repair. X Axis Shows The Various Tooth Groups Involved In Perforation Repair And Y Axis Shows The Number Of Teeth. The Results Show The Highest Incidence Of Perforation Repair Was Seen In 26 With 42.86% (Yellow).

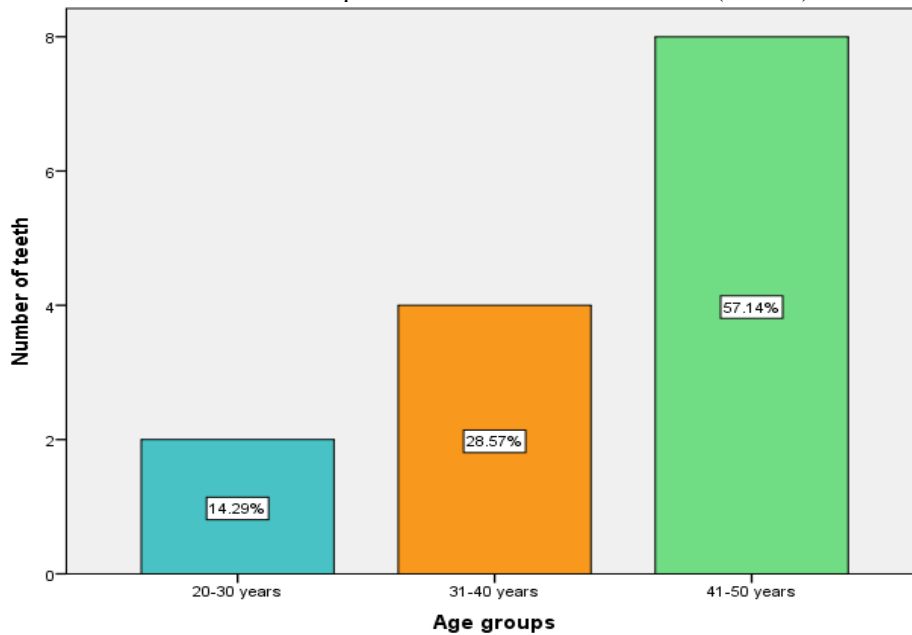


Figure 3: Bar Graph Depicts The Frequency Distribution Of Age Groups Involved In Perforation Repair In Relation To Maxillary Molars. X Axis Shows The Various Age Groups Involved In Perforation Repair In Relation To Maxillary Molars; Y Axis Shows The Number Of Teeth. The Results Show That The Perforation Repair Was Common In The Age Group Of 41-50 Years With 57.14% (Light Green).

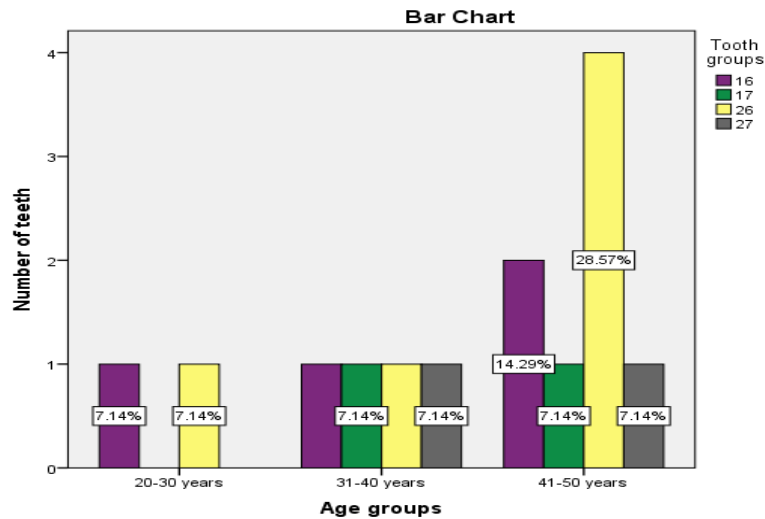


Figure 4: Bar Graph Depicts The Association Between Various Age Groups And Teeth Involved With Perforations. X Axis Represents The Various Age Groups And Y Axis Shows The Number Of Teeth. Chi-Square Test Was Performed And There Was No Statistically Significant Association Between Age Groups And Tooth Groups (Pearson Chi Square Value: 2.042; Df:6; P-Value: 0.916 > 0.05). However, Perforation Repair Was Common Among The Age Group Of 41-50 Years In Relation To 26 (28.57%, Yellow).